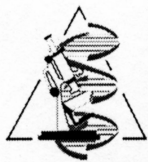

118271



CDL

OncoDiagnostic Laboratory, Inc
"A Partnership in Excellence"

C. H. Park, M.D., Lab Director
C.F. Galang, M.D., Co-Director
Y. S. Park, M.D., Pathologist
H. Xu, M.D., Ph.D., Pathologist
K. L. Cooper, M.D., Pathologist
G. Sharma, M.D., Pathologist

812 Huron Road Suite 520, Cleveland, Ohio 44115 Office: 216-861-5846 Fax: 216-861-1720 Toll Free: 800-527-6446 www.OncoDiagnostic.com

Account Name & Address

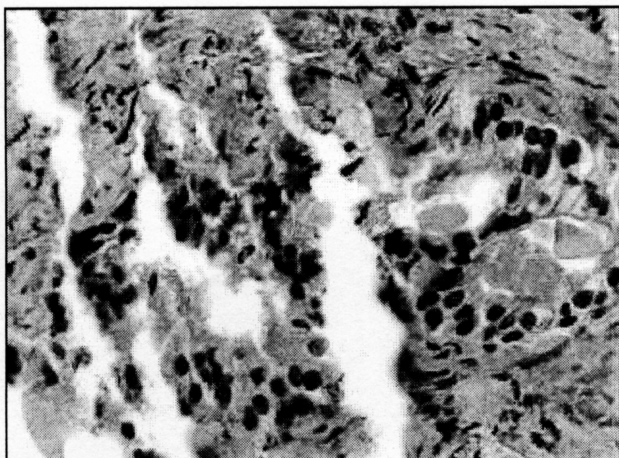
M-00104L*SV
DR. ALEXANDER LIU
1541 FLORIDA AVENUE, SUITE 100
MODESTO, CA 95350
Phone: (209) 577-3388 Fax: 12095214360
Cc: Cc: Cc:

Patient Name: HILL, DENNIS
Case Number: S2011-001000
Date of Birth: 07 08 1937
Age: 73
Collection Date: 01 25 2011
Received Date: 01 26 2011

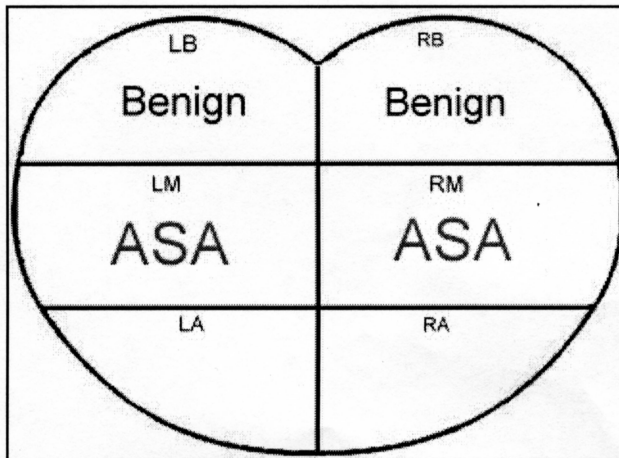
CLINICAL INFORMATION

Previous Bx: Malignant, 2/23/10

IMAGE



RM: Atypical small acini



Diagnosis summary

PROSTATE DIAGNOSIS

Site **Diagnosis**
LM: ATYPICAL SMALL ACINI WITH MARKED DRYING ARTIFACT (SEE COMMENT).
LB: BENIGN PROSTATIC TISSUE.
JB/GS/pp

Site **Diagnosis**
RM: ATYPICAL SMALL ACINI WITH MARKED DRYING ARTIFACT (SEE COMMENT).
RB: BENIGN PROSTATIC TISSUE.

COMMENT

Immunoperoxidase stains for the prostate triple panel (p504s, p63 and cytokeratin 34BE12) were performed on LM, LB and RM. The immunostains are non-contributory due to marked drying artifact. Clinical correlation, close follow-up and re-biopsy is advised. Control slide(s) were performed and are satisfactory.

GROSS DESCRIPTION

Bx Site	# Core/MM	# Slides Prepared	Bx Site	# Core/MM	# Slides Prepared
LM:	1 core	2 Histo; 3 Immunos	RM:	1 core	2 Histo; 3 Immunos
LB:	1 core	2 Histo; 3 Immunos	RB:	1 core	2 Histo